

## A MACHINE LEARNING APPROACH FOR DETECTION OF DIABETIC SYMPTOM ON HUMAN USING IRIS

P. Pinky\*<sup>1</sup>, Gargi Shankar Verma\*<sup>2</sup>

\*<sup>1</sup>M.Tech. Scholar, Columbia Institute Of Engineering & Technology, Dept. Of Computer Science And Engineering, Raipur, Chhattisgarh, India.

\*<sup>2</sup>Associate Professor, Columbia Institute of Engineering & Technology, Dept. of Computer Science and Engineering, Raipur, Chhattisgarh, India.

### ABSTRACT

Iris image investigation for clinical finding is quite possibly the most proficient harmless detection technique for deciding wellbeing status the diabetic patients. Right and opportune determination is a basic, yet fundamental prerequisite of clinical science. From the study, it is observed that cutting edge innovation additionally falls flat in part of cases to analyze infection accurately. The endeavor is being made to investigate the area of determination according to alternate points of view. By utilizing blend of precursor innovation Iridodiagnosis with present day innovation; Iridodiagnosis is an elective part of clinical science, which can be utilized for symptomatic purposes; To start with an information base is made of iris images with clinical history of subject's accentuation on diabetic (type II) illness in obsessive research center. The different calculations using deep learning approach will be produced for image quality evaluation, division of iris, iris standardization and clinical component grouping for clinical finding. A huge improvement is normal in characterization execution over the current methodologies through our proposed technique. Proposed technique archives around 96% and 86% of accuracy while training and testing iris datasets.

**Keywords:** Deep Learning, Diabetes, Iris Images Segmentation, Machine Learning, Iris, Medical, Clinical, Diagnosis.

### I. INTRODUCTION

Diabetes is an illness that happens in light of the fact that the body can't create the chemical insulin or the body can't utilize insulin successfully, causing an expansion in blood glucose levels in the body [1]. Insulin is a chemical delivered by beta cells in the pancreas and transports glucose from the circulatory system to body cells. There are three kinds of diabetes, specifically type I, type II, and gestational diabetes. Type I happens in light of the fact that the safe framework assaults beta cells in the pancreas, with the outcome that pancreas produces insulin in modest quantities [2]. Type II is the most widely recognized type of diabetes portrayed by hyperglycemia due to inadequate of insulin creation, and the incapability of the body is reacting to insulin [3]. While gestational diabetes is a kind of diabetes that assaults pregnant ladies who have a high blood glucose level during pregnancy [4].

The International Diabetes Federation (IDF) gauges that around 425 million individuals are impacted diabetes in 2017 and will increment by around 48% in 2045 to around 629 million individuals worldwide with an age scope of 20-79 years. In view of IDF information, Indonesia is among the 10 nations with the most diabetic populace, and positions sixth after China, India, US, Brazil, and Mexico with 10.3 million individuals, and will increment to 10.6 million of every 2045 [4].

In view of IDF information, of the 10.3 million Indonesians impacted by diabetes, around 73.7% or 7.6 million individuals were not identified early. Delays in identifying diabetes can prompt serious impacts or confusions from different infections, for example, waterfalls, glaucoma, stroke, coronary failure, and diabetic retinopathy. There are a few traditional strategies used to learn about diabetes, for example, estimating glucose through pee, blood, eye liquids, sweat and spit [5], and with the hemoglobin test. Notwithstanding, a portion of these strategies are obtrusive and required example arrangement ahead of time. Iridology can be a choice to aid the most common way of recognizing diabetes. Iridology is an elective clinical science that associates designs, shapes, colors, tissue harm, and different characters in the iris that can be utilized to get data about the wellbeing status of the body [6].

The eye is produced using three layers: an external layer of connective tissue, a center vascular layer, and an inside neural layer. The fundamental plans can be found in Figure, which portrays the lower part of the right

eye. The external layer intertwines the cornea, which is clear, and the sclera, reliably known as the "white" of the eye. Within layer, or the retina, contains photoreceptors, which change photon energy into neural signs. The center layer is known as the urea and contains the iris, culinary body, and choroid [7]. The iris, a concealed ring of muscles and connective tissue, is the furthest of the three urea plans and controls reaching out of the understudy, which moves the extent of light that goes through. The extent of the iris is 12 mm all around, and the scope of the understudy can go from 0.5 mm to 4.5 mm relying on extension.

During lacking movement, the neural chamber ectoderm and mesenchyme long term accomplish the iris. After week 3, the optic cup structures as the harbinger to the eye. The main segment of the optic cup traces the iris and culinary body epithelia. The principal segment of the optic cup's inner layer, the greater part of which shapes the neural retina, accomplishes the non-pigmented cells of the iris. Neural apex cells structure the stoma, and the sphincter and dilator muscles make from neuroectoderm. A gigantic piece of this progress happens before week 10 of the starting animal's life.

#### **NEED FOR DIAGNOSIS TECHNIQUE:**

##### **A. Kidneys in the Iris**

Kidney iris zones all the time show enormous injuries called medussas and radials. They similarly appear as white blazing, or sub-extreme with dull disguising. Inborn inadequacy or kidney injuries ought to be carefully studied and laid out deficiencies evaluated. Look for lymphatic tophi in the kidney district. Blockage of lymph or lacking blood stream to the kidneys will cause issues.

##### **B. Lung Signs in the Iris**

A collection of iris markings uncovers information about the condition of the lungs. Inborn inadequacy shows up as open or closed wounds got together with colors from white to dull. See whether an inside pocket or radii Solaris intensifies the condition by sending toxins to the domain. Reflexive strands (regardless of whether swollen or pink) uncover expanded degrees of disturbance. Notice the state of the assimilation ring, the state of the ANW, the lymphatic rosary.

## **II. LITERATURE SURVEY**

Most employments of iris-related imaging have been normal for biometrics and perceiving affirmation of people. One of the earliest applied plans for mechanized iris biometrics was approved in 1987 by Flom and Safir, yet was unimplemented [6]. During the 1990s, Daugman started laying the foundation for a huge load of iris biometrics basics, and without a doubt a lot of business advancement is now dependent upon his work.

A piece of the eye that is routinely utilized in imaging-based diagnostics is the retina. Organized toward the rear of the eye, the retina can be imaged through a fundus camera, ophthalmoscope, or optical amplexness tomography, to give a couple of models.

Bonomi L et al. (2000)] expressed that glaucoma of open point fundamental sort is more found in eyes having low perfusion pressure. The full scale number of diabetic patients are high in bundle I ( patients with low perfusion pressure ) cases are 22.4% diverged from pack II ( patients with normal perfusion pressure) are 12.7% and the presence of basic differentiation attests that diabetes is one of the risk element to make glaucoma of open point fundamental sort [11].

Vikash Chopra et al1 in his general population - based cross - sectional assessment, investigated the "connection between type 2 diabetes mellitus (T2 DM) and the risk of having open - point glaucoma (POAG ) in an adult Latino people" . The assessment contemplated that the sort II DM occasion and a years of type II DM were independently associated with a high risk of making POAG in the LALES accomplice [12].

Simone de voogd et al. did a general population - based fast approaching accomplice study to investigate diabetes mellitus related as high risk for glaucoma of open point fundamental sort . This Rotterdam study was done in Netherlands and the follow - up period was three years. This assessment clearly showed that the diabetic patients didn't have any extended risk of making POAG [13].

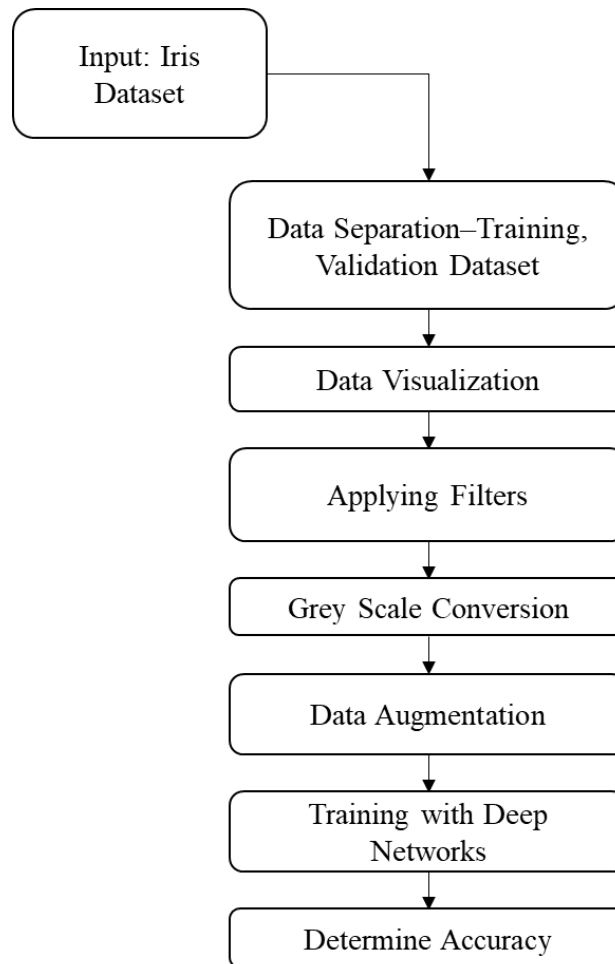
M. Christina Leski et al surveyed " the risk factors for unequivocal Primary open - point glaucoma ( OAG ), taking into account African - drop individuals from the Barbados Eye Studies". It was a partner report having a follow - up season of nine years. This was an early evaluation for peril parts of glaucoma of open point

fundamental sort recurrence long length. The examination is again established on a respectable volume of as of late broke down patients [14].

### III. METHODOLOGY

This section delas with the proposed methodology. The system comprises of various modules. They are:

1. Input of Iris dataset.
2. Data separation and visualization.
3. Data preprocessing such as applying filters and Grey scale conversion.
4. Data Augmentation.
5. Training and Testing dataset.



**Fig 1:** Shows the system architecture

#### Iris Image Dataset

The iris image is collected from the Shri Ganesh Vinayak Eye Hospital, Raipur, Chhattisgarh. The snapshot of the dataset is shown in below figure.

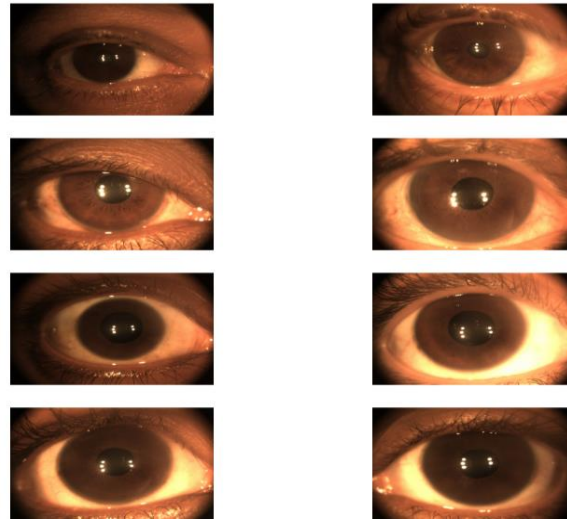


Fig 2: Shows the Iris dataset snapshot

### Preprocessing

Before providing these images to the deep learning networks we need first to pre-process it so that the noises are removed. We here apply various filters for machine learning classifier to learn. They are:

1. Blur filter
2. Contour filter
3. Emboss filter
4. Edge enhance filter
5. More edge enhance filter

### Grey scale conversion

The machine learning networks works better with the grey scale images. Hence the coloured images are converted to grey scale.

### Data Augmentation

The presentation of profound learning neural organizations regularly improves with how much information accessible. Information increase is a strategy to misleadingly make new preparation information from existing preparation information. This is finished by applying space explicit strategies to models from the preparation information that make new and different preparation models. Picture information increase is maybe the most notable kind of information expansion and includes making changed forms of pictures in the preparation dataset that have a place with a similar class as the first picture. Changes incorporate a scope of activities from the field of picture control, like movements, flips, zooms, and considerably more.

### Deep learning training

After processing and augmentation, the data set are ready to be processed by the deep learning networks. The deep learning networks consists of multiple networks for processing the pixel of information.

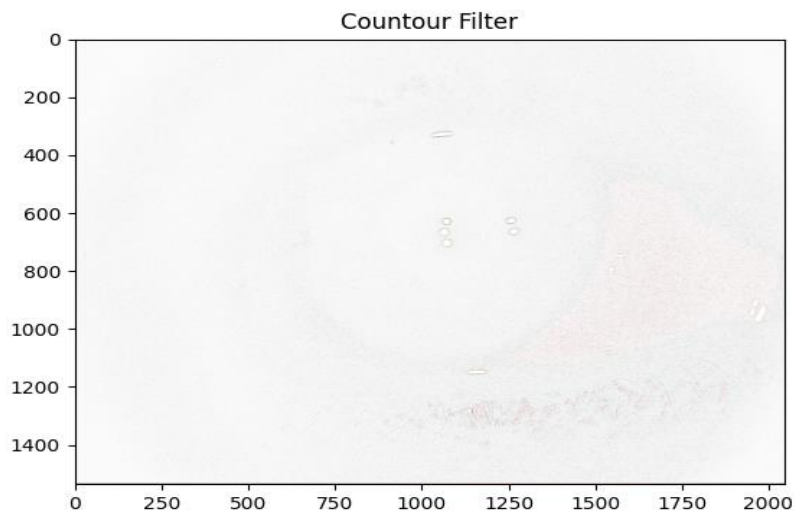
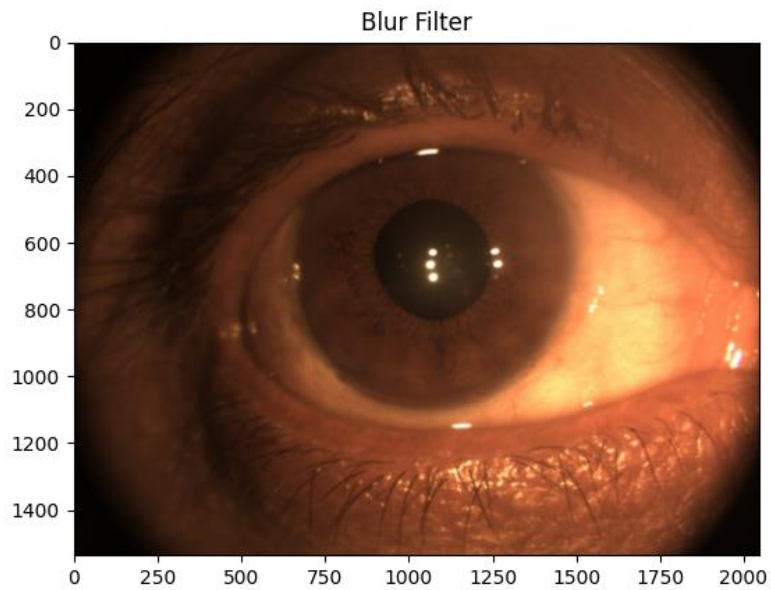
## IV. RESULTS

This section shows the experimental result performed through the python GUI software.

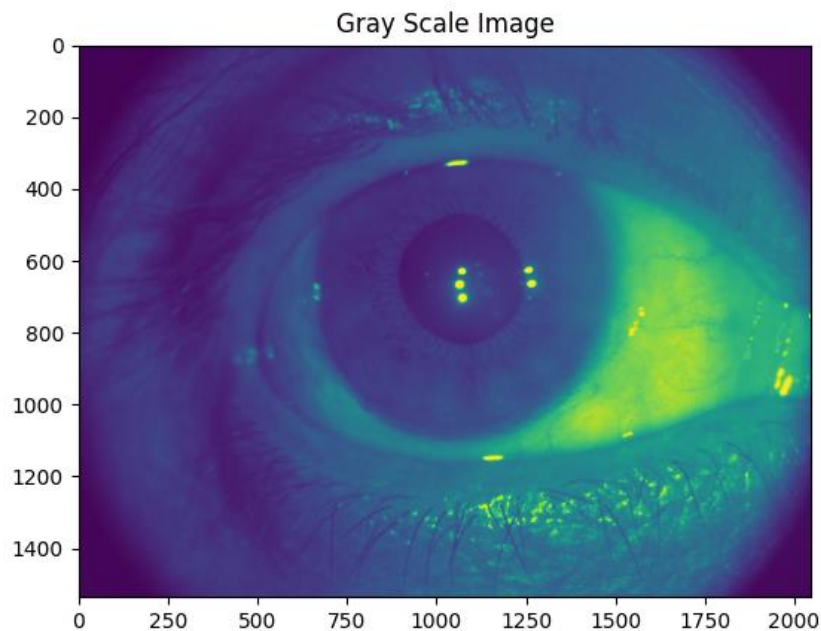
### Step 01: Training and Test data input

```
C:\Windows\System32\cmd.exe - python main.py
total training diabetic images: 25
total training nondiabetic images: 19
total validation diabetic images: 5
total validation nondiabetic images: 5
```

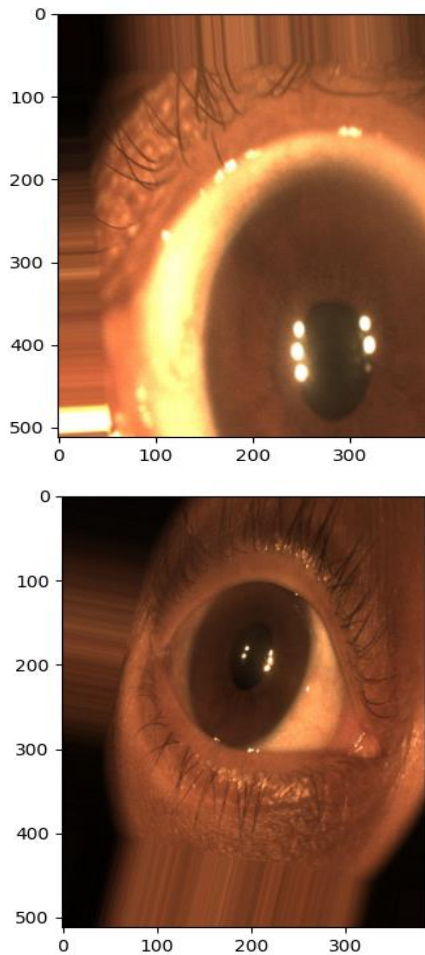
**Step 02: Filters**



**Step 03: Grey scale image conversion**



**Step 04: Augmentation**

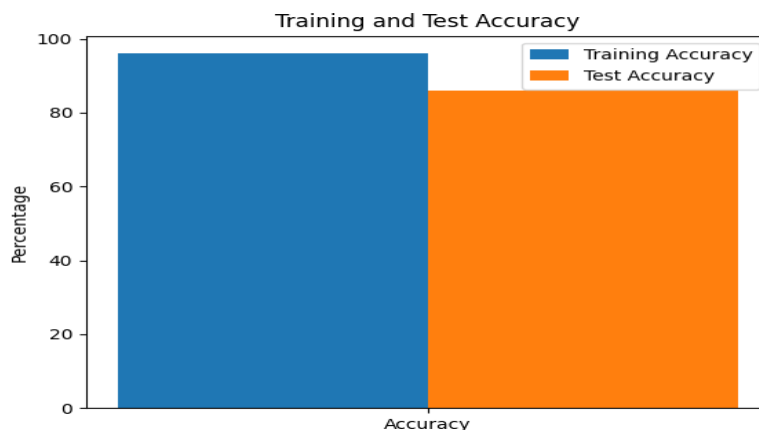


**Step 05: Training**

```

Model: "sequential"
-----
Layer (type)                Output Shape              Param #
-----
flatten (Flatten)           (None, 589824)            0
dense (Dense)                (None, 128)               75497600
dense_1 (Dense)             (None, 1)                 129
-----
Total params: 75,497,729
Trainable params: 75,497,729
Non-trainable params: 0
    
```

**Accuracy**



## V. CONCLUSION

The input images of iris are given as input. The features are extracted and processed by our framework. The classification algorithm classifies the images and produces output that the iris is of diabetic patient or normal patient. The accuracy obtained are 96% and 86% for training and test respectively. This shows that our proposed method is almost nearer to true outcomes of clinical results.

## VI. REFERENCES

- [1] R. A. DeFronzo, E. Ferrannini, K. G. M. M. Alberti, P. Zimmet, and G. Alberti, International Textbook of Diabetes Mellitus. 2015.
- [2] S. Canivell and R. Gomis, "Diagnosis and classification of autoimmune diabetes mellitus," *Autoimmun. Rev.*, vol. 13, no. 4–5, pp. 403–407, 2014.
- [3] Olokoba, O. Obateru, and L. Olokoba, "Type 2 Diabetes: a Review of Current Trends -," *Int. J. Curr. Res. Rev.*, vol. 7, no. 18, pp. 61–66, 2015.
- [4] D. Atlas, IDF Diabetes Atlas. 2017.
- [5] D. Bruen, C. Delaney, and L. Florea, "Glucose Sensing for Diabetes Monitoring: Recent Developments," vol. 17, 2017.
- [6] Jensen, "Iridology Simplificated," Bernard Jensen Enterprises CA 92025, Calif., 1980.
- [7] P. E. Harris, K. . Cooper, C. Relton, and K. . Thomas, "Prevalance of complementary and alternative medicine (CAM) use by the general population : A systematic review and update," *Int. J. Clin.*, vol. 66, pp. 924–939, 2012.
- [8] Bonomi L et al. Vascular risk factors for primary open angle glaucoma: the Egna Neumarkt Study; *Ophthalmology* 2000 Jul;107(7):1287-93.
- [9] Chopra V, Varma R, Francis BA, et al. Los Angeles Latino Eye Study Group. Type 2 diabetes mellitus and the risk of open-angle glaucoma: the Los Angeles Latino Eye Study. *Ophthalmology* 2008;115:227-32.
- [10] de Voogd S, Ikram MK, Wolfs RC, et al. Is diabetes mellitus a risk factor for open-angle glaucoma The Rotterdam Study. *Ophthalmology* 2006;113:1827-31.
- [11] Leski MC, et al: Patterns of open-angle glaucoma in the Barbados Family Study, *Ophthalmology* 108:1015, 2.